NEURO INSTITUTE

Continuing Education for Rehabilitation Professionals

Post Traumatic Hydrocephalus

Clausyl Plummer II, M.D.

Disclosures

- None

Learning Objectives

- 1) Identify the most common clinical presentations in post-traumatic hydrocephalus
- 2) Discuss the pathophysiology of hydrocephalus after traumatic brain injury
- 3) Apply a framework for management of post-traumatic Hydrocephalus.

Neuro Restorative™
Rebuilding Lives. Restoring Hope.

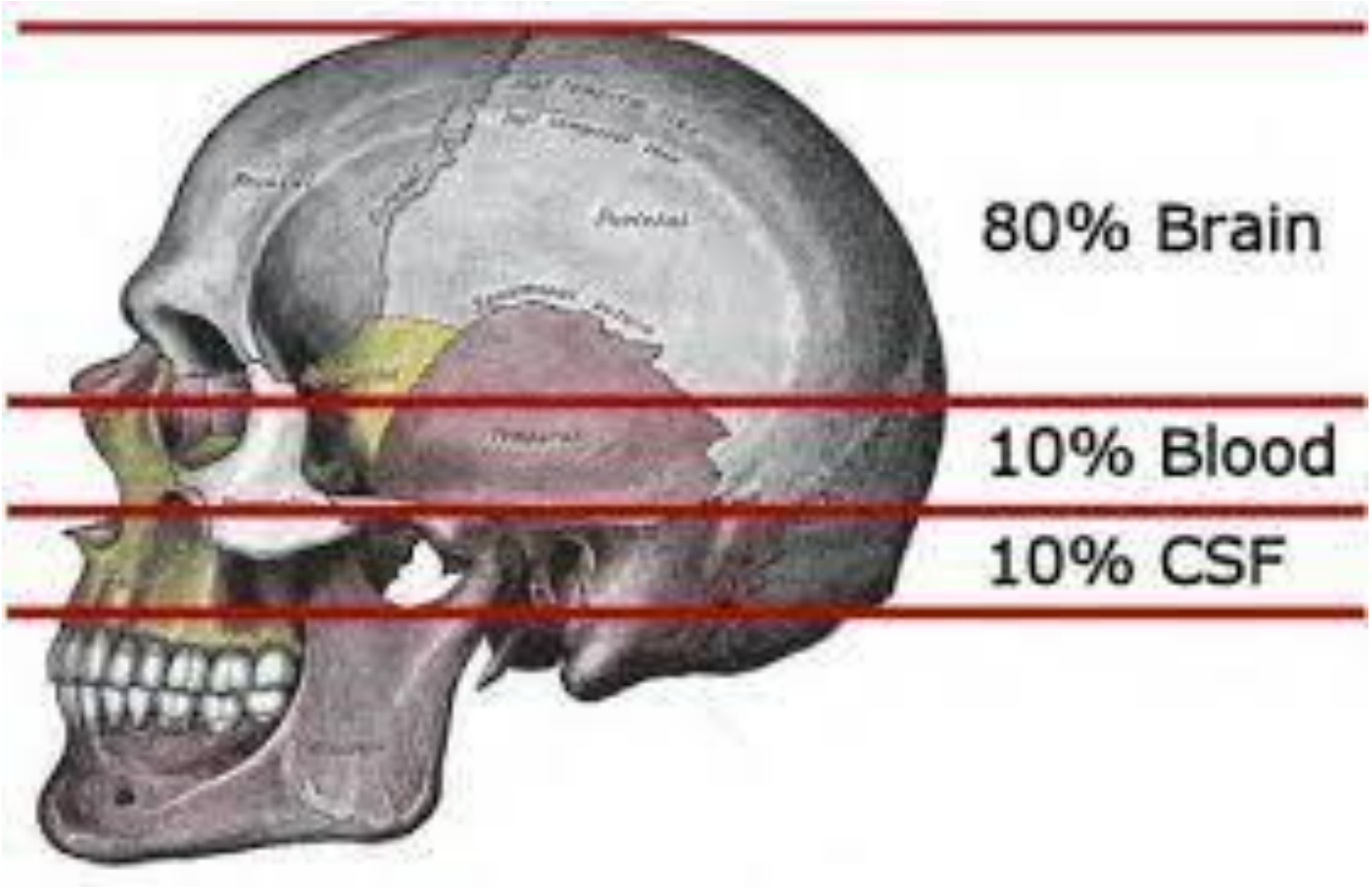

What we will discuss

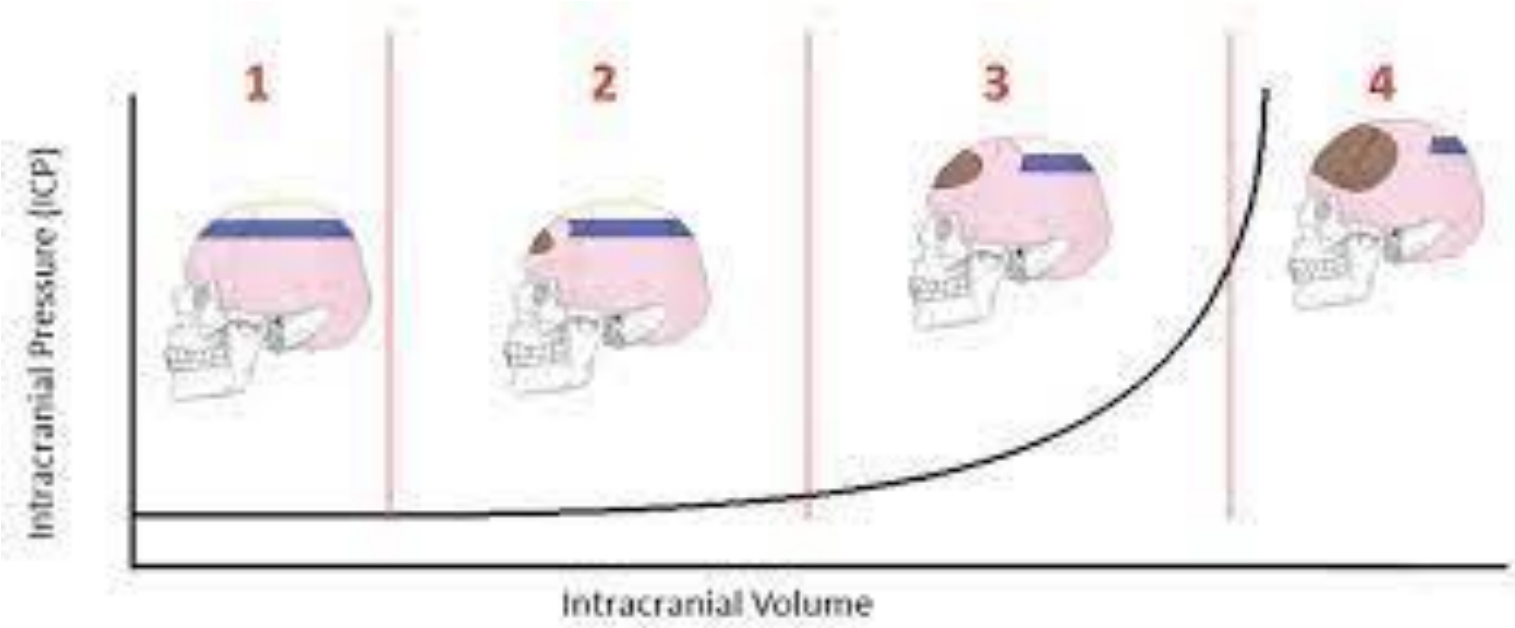

Definition

"Condition in which excess cerebrospinal fluid (CSF) builds up within the fluid-containing cavities or ventricles of the brain." -AANS

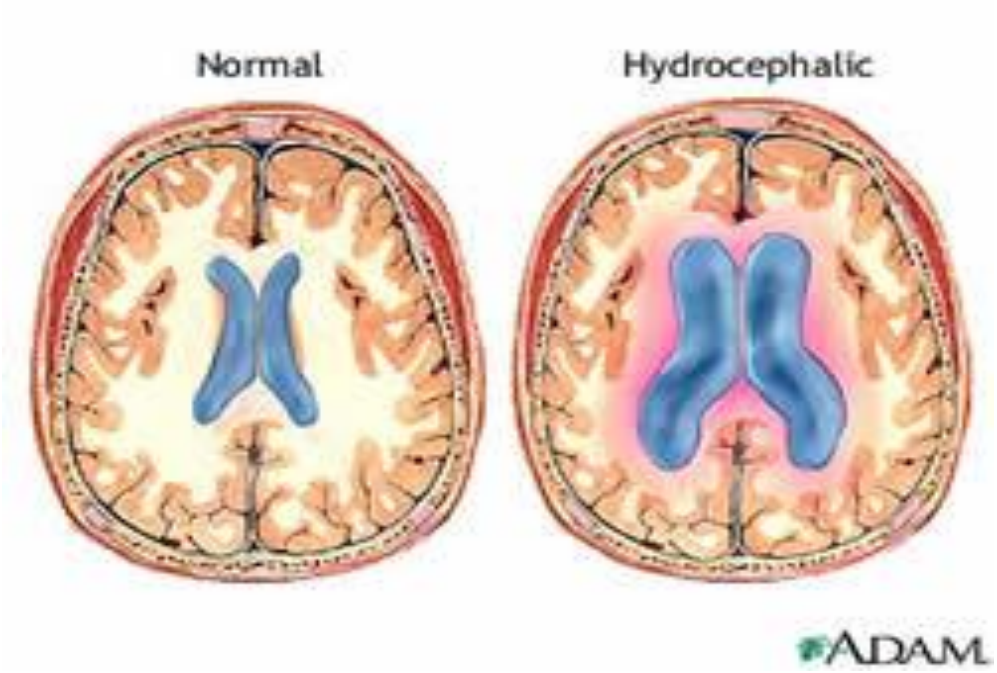

https://neurosurgery.ufl.edu/patient-care/diseases-conditions/hydrocephalus/

History

Neuro Restorative™
Rebuilding Lives. Restoring Hope.

Neuro Restorative™
Rebuilding Lives. Restoring Hope.

History

Neuro Restorative™
Rebuilding Lives. Restoring Hope.

- First Traumatic case described in 1914 by Dandy and Blackfan (1914).
  - Pediatric case after a fall
- Hippocrates 5th century BC
- Diemerbroeck linked hydrocephalus to "*bad nutrition and poor feeding*"
  - Enlargement of an 18-month-old child's head; he described it to be "as big as a man's head."
  - His theory involved production of copious amounts of phlegm and thick fluids that came from the intestines to the skull.

Demerdash, A., Singh, R., Loukas, M. *et al.* A historical glimpse into treating childhood hydrocephalus. *Childs Nerv Syst* **32**, 405–407 (2016). https://doi.org/10.1007/s00381-015-2652-3

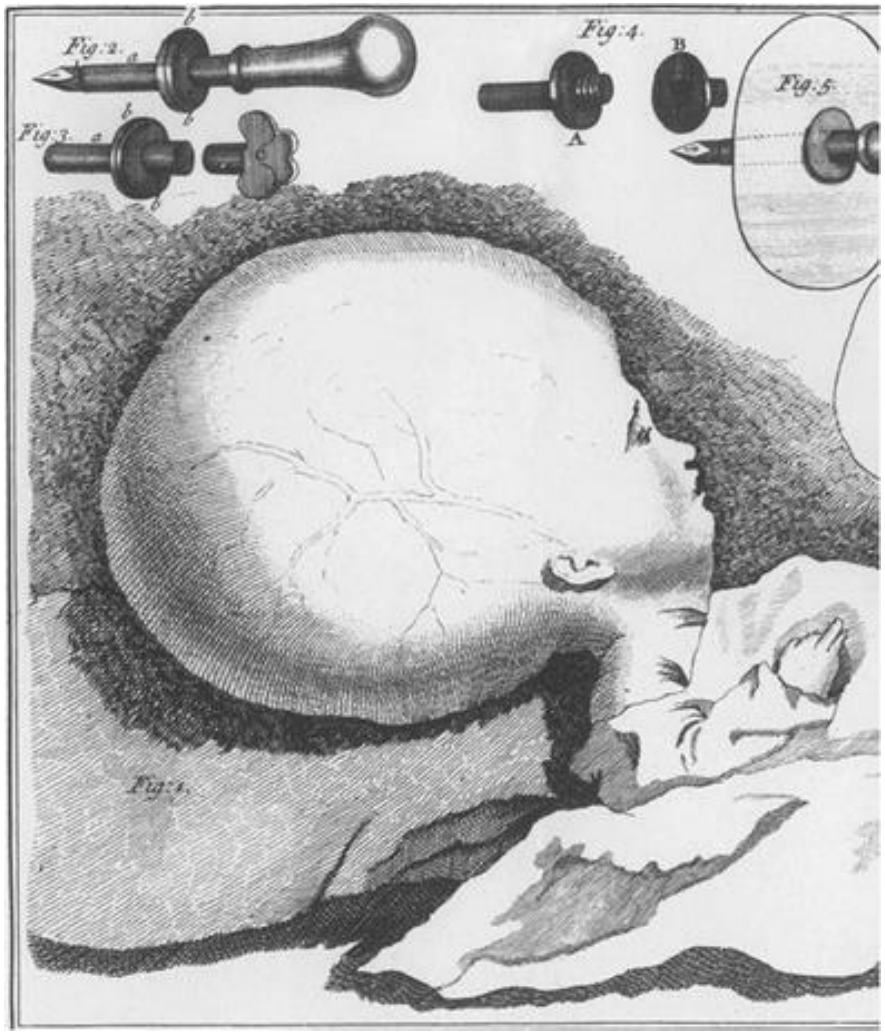

Demerdash, A., Singh, R., Loukas, M. *et al.* A historical glimpse into treating childhood hydrocephalus. *Childs Nerv Syst* **32**, 405–407 (2016). https://doi.org/10.1007/s00381-015-2652-3

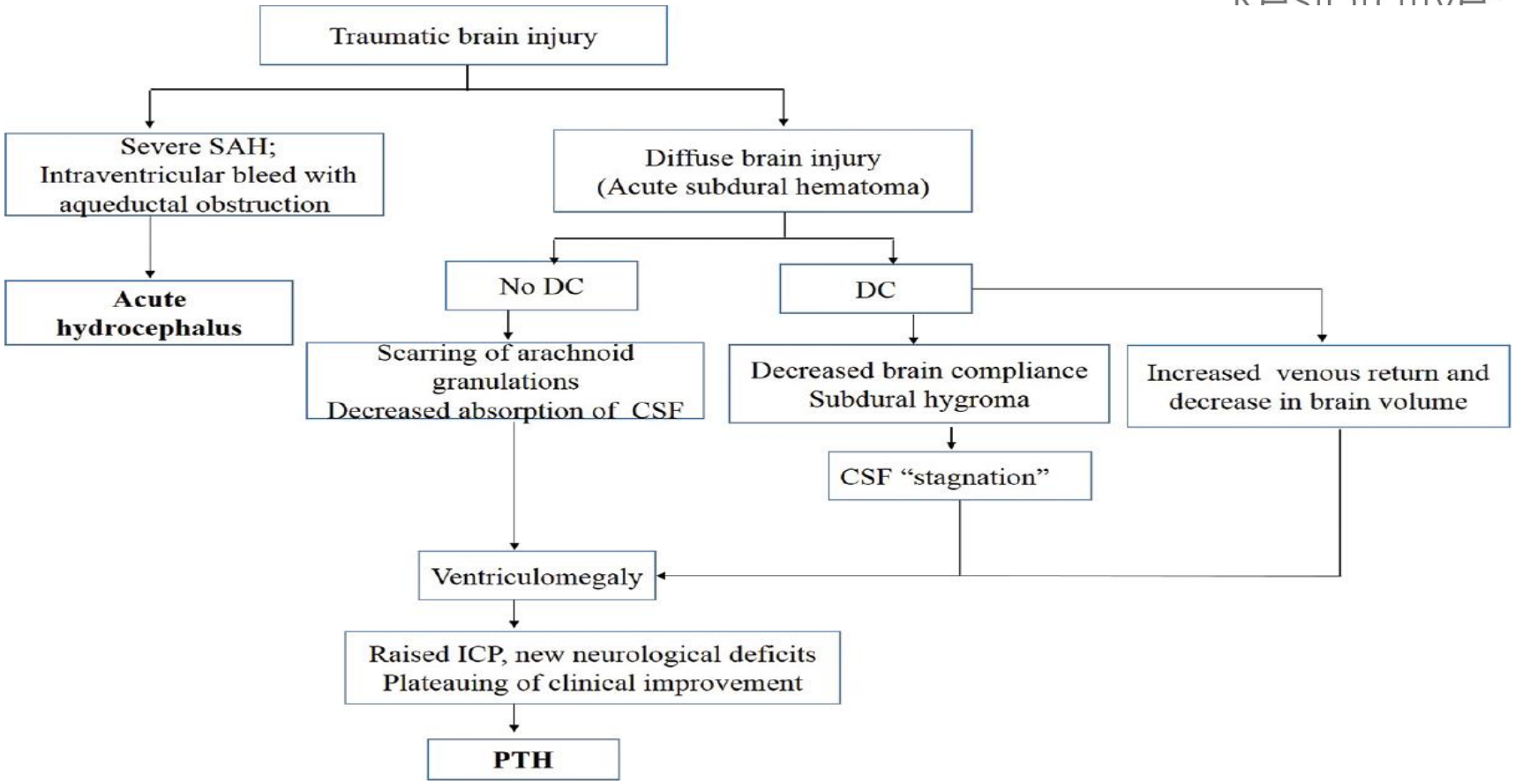

Rufus P, Moorthy RK, Joseph M, Rajshekhar V. Post Traumatic Hydrocephalus: Incidence, Pathophysiology and Outcomes. Neurol India 2021;69, Suppl S2:420-8

Risk Factors

Tien et.al 2007

Neuro Restorative™
Rebuilding Lives. Restoring Hope.

- Goal: To assess the occurrence of hydrocephalus in patients with tSAH
  - Also, to investigate the risk factors for the development of hydrocephalus after tSAH.
- 301 patients evaluated over 3 month period:
  - 36 (11.96%) developed hydrocephalus
    - Hydrocephalus appeared after injury within the first week in 3 pts (8.33%)
    - 2 weeks to 1 month in 25 pts (69.44%)
    - 1 to 3 months in 8 pts (22.22%)

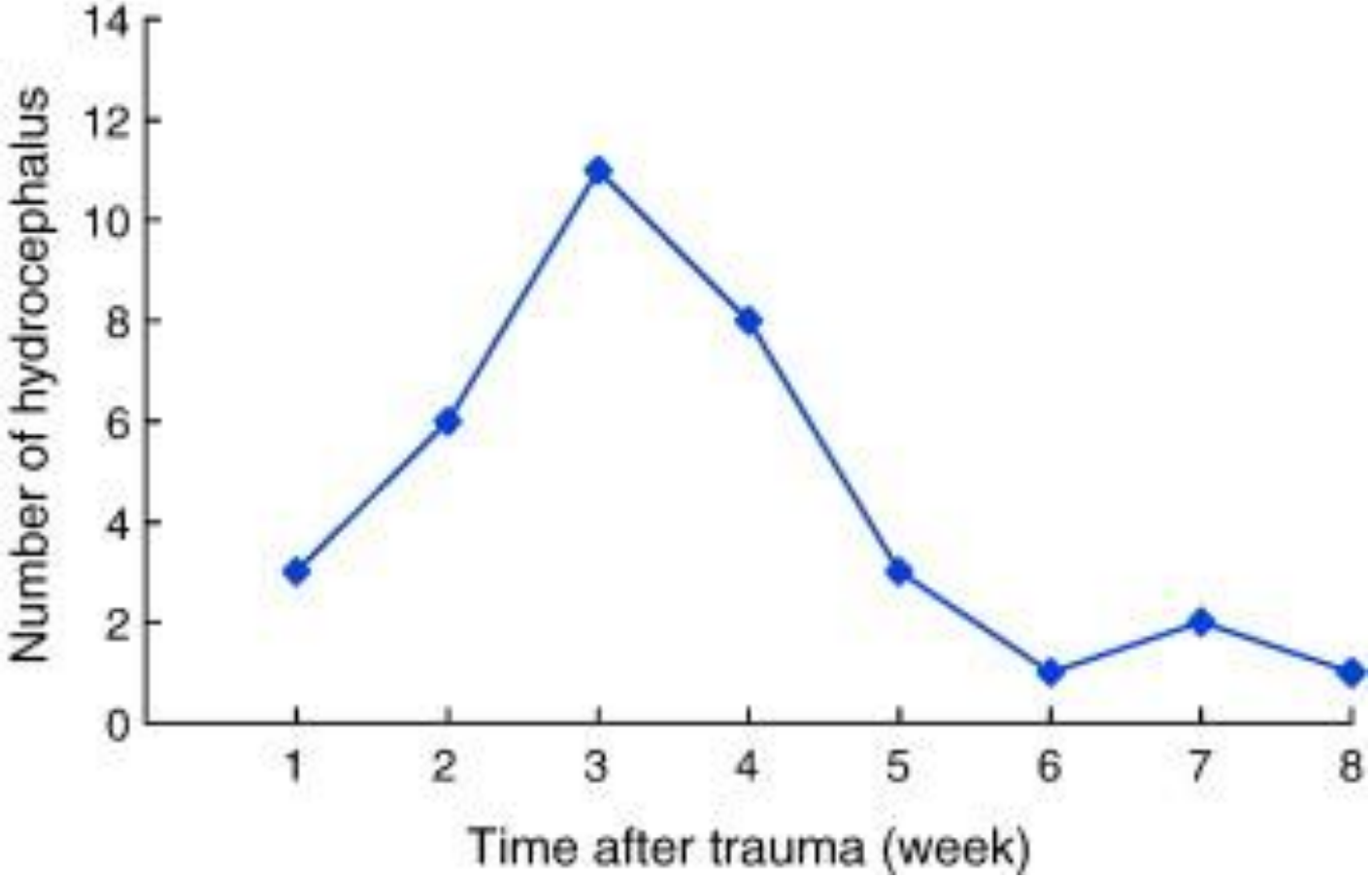

Tian HL, Xu T, Hu J, Cui YH, Chen H, Zhou LF. Risk factors related to hydrocephalus after traumatic subarachnoid hemorrhage. Surg Neurol. 2008 Mar;69(3):241-6; discussion 246. doi: 10.1016/j.surneu.2007.02.032. Epub 2007 Aug 17. PMID: 17707493.

Table 3. Multivariate logistic regression analysis of the association between risk factors and hydrocephalus

Factors	OR value	95% CI	*P*
Sex	1.500	0.622-3.621	.3667
Age (y)	1.932	1.124-3.320	.0172
GCS score	1.324	0.752-2.332	.3306
Craniotomy	1.018	0.436-2.378	.9672
Location of tSAH	0.998	0.413-2.415	.9969
Distribution of tSAH	3.611	1.381-9.442	.0088
Thickness of tSAH	4.117	1.792-9.456	.0009
Intraventricular hemorrhage	6.561	2.755-15.626	.0001

Tian HL, Xu T, Hu J, Cui YH, Chen H, Zhou LF. Risk factors related to hydrocephalus after traumatic subarachnoid hemorrhage. Surg Neurol. 2008 Mar;69(3):241-6; discussion 246. doi: 10.1016/j.surneu.2007.02.032. Epub 2007 Aug 17. PMID: 17707493.

Sun et. al 2019



Diagnostic criteria:

- (1) Gudeman criterion
- (2) Evans index

- Gudeman Criteria
  - Enlargement of lateral ventricle and the three ventricles
  - With or without the presence of the cerebral sulcus on serial CT scan

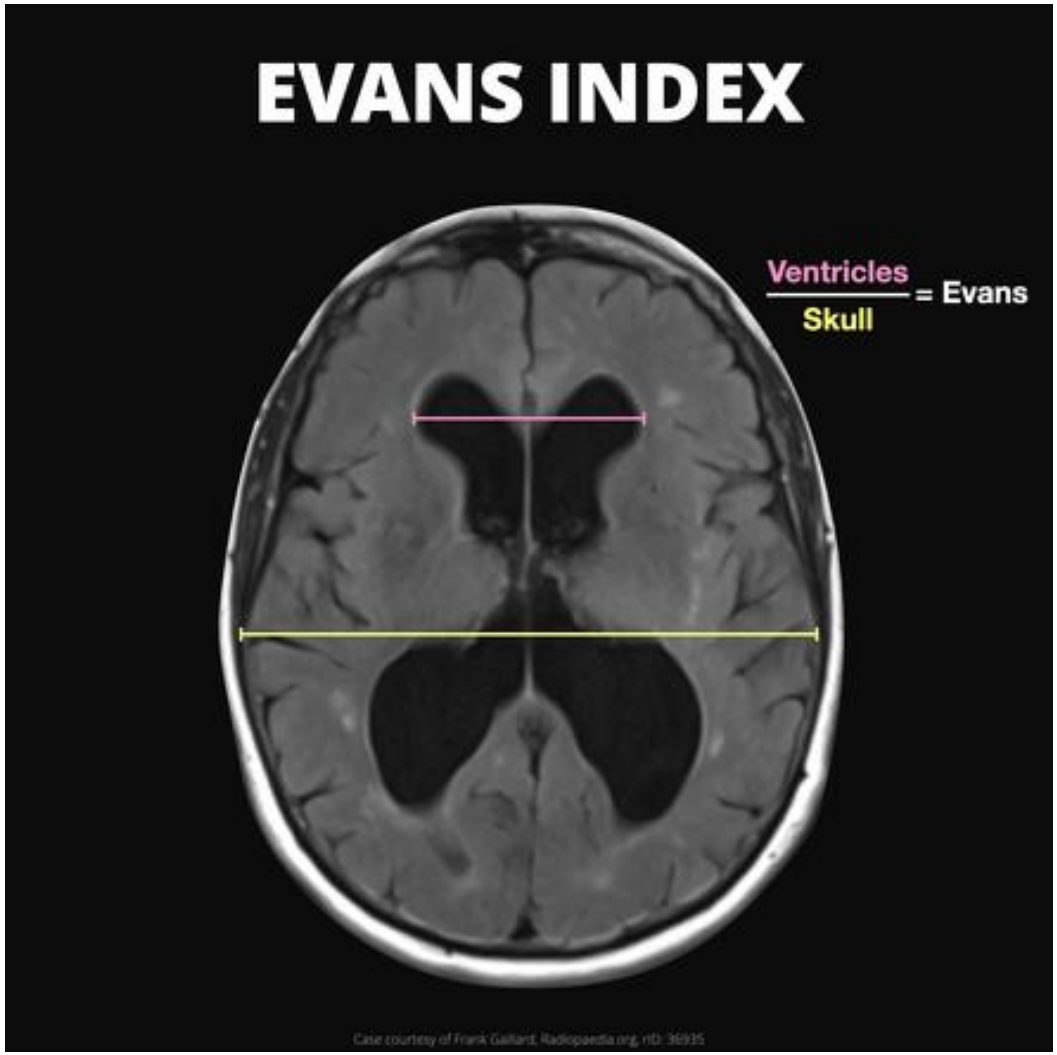

https://radiopaedia.org/articles/evans-index-2?lang=us

Clinical Criteria:

- neurobehavioral and cognitive impairment
- Increased flap tension in patients undergoing DC
- No improvement or deterioration of consciousness in patients with coma.

Interpretation

- 0.20-0.25: normal
- 0.25-0.30: possible or early ventriculomegaly
- >0.30: ventriculomegaly

Sun S, Zhou H, Ding Z-Z, Shi H. Risk Factors Associated with the Outcome of Post-Traumatic Hydrocephalus. Scandinavian Journal of Surgery. 2019;108(3):265-270. doi:10.1177/1457496918812210

Results

- 33.6% (39/116) of the patients evaluated had a good outcome
- 66.4% (77/116) were with poor outcome
- 6.9% (8/116) died

Neuro Restorative™
Rebuilding Lives. Restoring Hope.

Factors	OR	95% CI	p value
Cisterna ambiens disappearance	9.190	1.976–42.751	0.005
Duration of comatous state >2 months	7.906	1.840–33.969	0.005
Plasma fibrinogen increase	5.377	1.211–23.880	0.027
V-P shunt	0.167	0.036–0.772	0.002

OR: odds ratio; CI: confidence interval; V-P: ventriculoperitoneal.

Sun S, Zhou H, Ding Z-Z, Shi H. Risk Factors Associated with the Outcome of Post-Traumatic Hydrocephalus. Scandinavian Journal of Surgery. 2019;108(3):265-270. doi:10.1177/1457496918812210

Presentation

Case

Neuro Restorative™
Rebuilding Lives. Restoring Hope.

- 63 yo RHD F with recent severe TBI presented to clinic for TBI follow up 3 months after her injury date.
- She was acutely managed at an OSH and after 1 month, she was transferred to acute inpatient rehabilitation, where she stayed for 1 month.
- She was discharged home at a supervision level with ADLs, ambulation, and in cognition.

Case

Neuro Restorative™
Rebuilding Lives. Restoring Hope.

- Unfortunately, she started declining functionally (ambulation issues, cognitive changes, urinary urgency/incontinence).
- Brain MRI revealed dilated lateral ventricles, Evans ratio>0.3, encephalomalacia. No acute intracranial bleeds.
- Referral for NSY for workup, surgical consideration.

Presentation

- Alterations in:
  - Memory
  - Urinary incontinence
  - Gait changes

- Can also present as a syndrome of increased intra-cranial pressure:
  - Papilledema
  - Focal neurologic deficits

Work up

Radiographic findings

- An increase in ventricular size:
  - Rounded appearance of the frontal horns
  - Enlargement of the temporal horns and third ventricle
  - Absence of the sulci
  - Enlargement of the basilar cisterns and the fourth ventricle

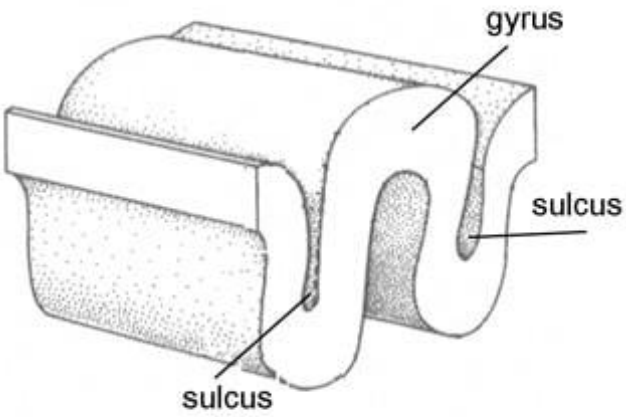
gyrus
sulcus
sulcus

Neuro Restorative™
Rebuilding Lives. Restoring Hope.

Passos-Neto CEB, Lopes CCB, Teixeira MS, Studart Neto A, Spera RR. Normal pressure hydrocephalus: an update. Arq Neuropsiquiatr. 2022 May;80(5 Suppl 1):42-52. doi: 10.1590/0004-282X-ANP-2022-S118. PMID: 35976308; PMCID: PMC9491444.

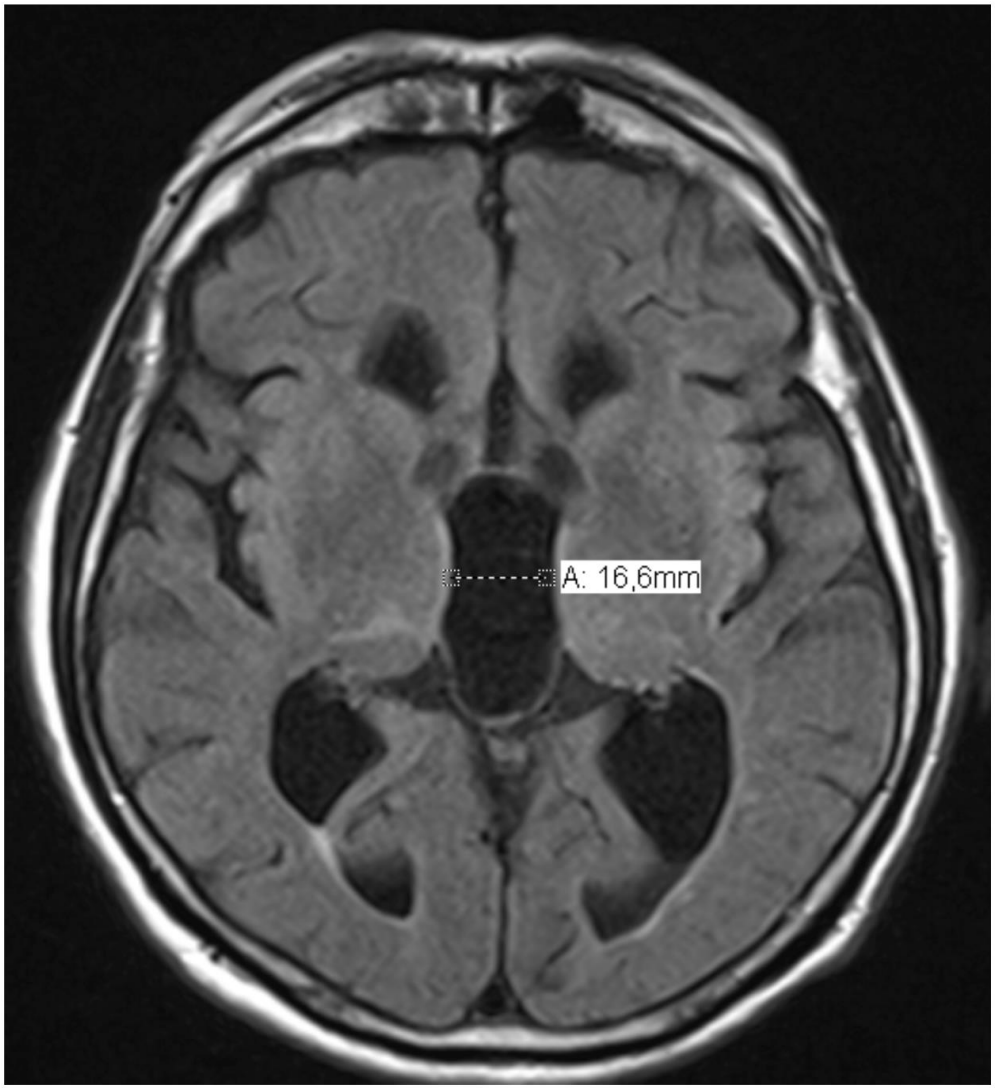

Passos-Neto CEB, Lopes CCB, Teixeira MS, Studart Neto A, Spera RR. Normal pressure hydrocephalus: an update. Arq Neuropsiquiatr. 2022 May;80(5 Suppl 1):42-52. doi: 10.1590/0004-282X-ANP-2022-S118. PMID: 35976308; PMCID: PMC9491444.

Lumbar Puncture

- Large volume Lumbar puncture (“Tap Test”)
- External lumbar Drain

- Pre/Post testing:
    - Gait
    - Cognition
    - Voiding

Passos-Neto CEB, Lopes CCB, Teixeira MS, Studart Neto A, Spera RR. Normal pressure hydrocephalus: an update. Arq Neuropsiquiatr. 2022 May;80(5 Suppl 1):42-52. doi: 10.1590/0004-282X-ANP-2022-S118. PMID: 35976308; PMCID: PMC9491444.

Treatment

Neuro Restorative™
Rebuilding Lives. Restoring Hope.

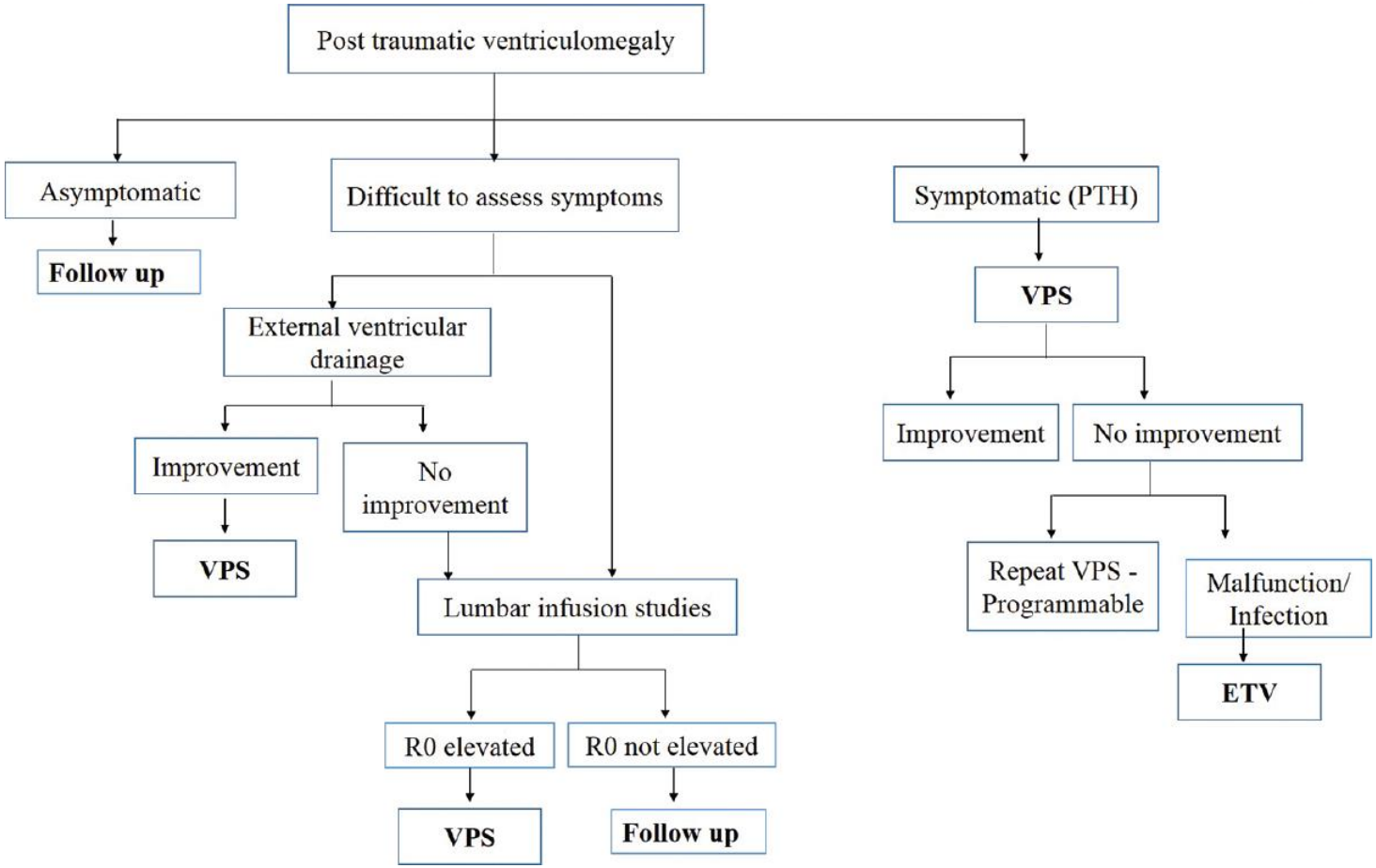

Rufus P, Moorthy RK, Joseph M, Rajshekhar V. Post Traumatic Hydrocephalus: Incidence, Pathophysiology and Outcomes. Neurol India 2021;69, Suppl S2:420-8

Surgical Interventions

- Ventriculo-peritoneal shunt
- Ventriculo-atrial shunt
- Lumbo-peritoneal shunt

- Endoscopic third ventriculostomy

Passos-Neto CEB, Lopes CCB, Teixeira MS, Studart Neto A, Spera RR. Normal pressure hydrocephalus: an update. Arq Neuropsiquiatr. 2022 May;80(5 Suppl 1):42-52. doi: 10.1590/0004-282X-ANP-2022-S118. PMID: 35976308; PMCID: PMC9491444.

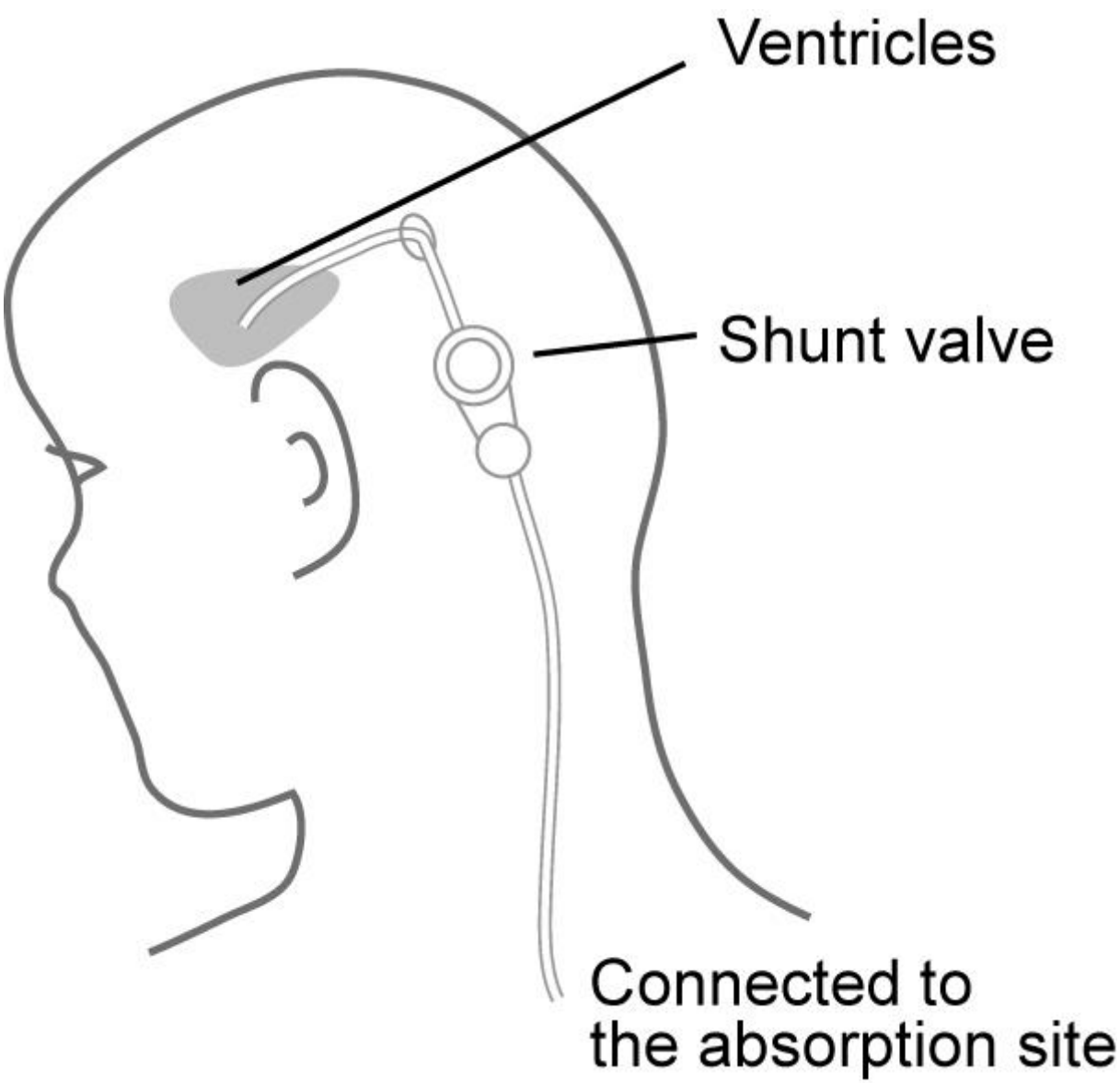

Neuro Restorative™
Rebuilding Lives. Restoring Hope.

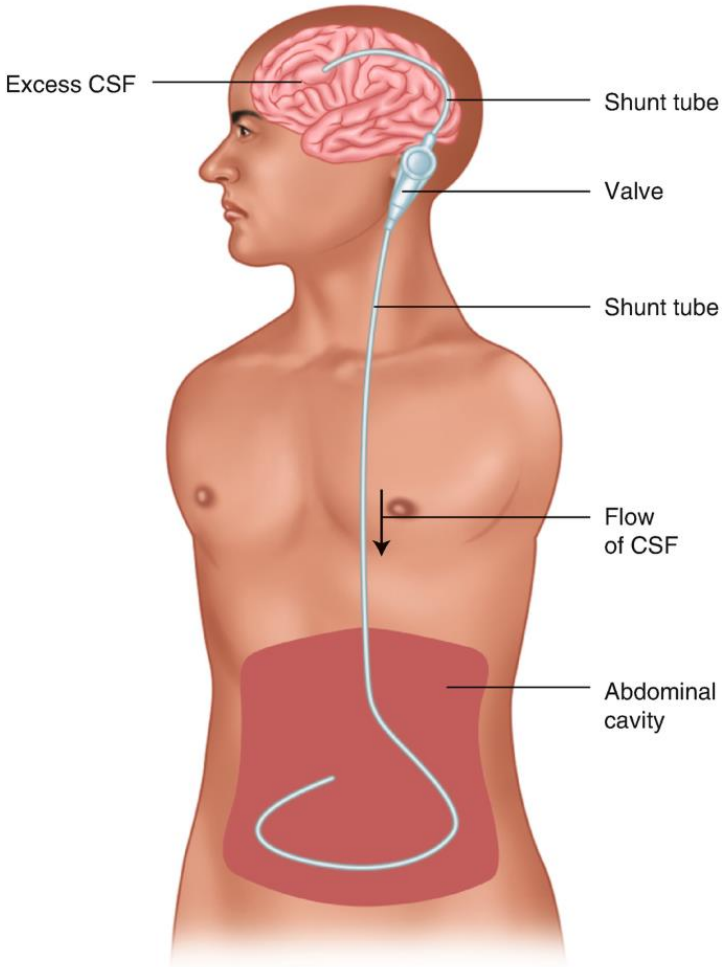

Umansky, A., Elbadri, S., Desai, B.K. (2022). Ventriculoperitoneal Shunt Tap. In: Ganti, L. (eds) Atlas of Emergency Medicine Procedures. Springer, Cham. https://doi.org/10.1007/978-3-030-85047-0_50

Neuro Restorative™
Rebuilding Lives. Restoring Hope.

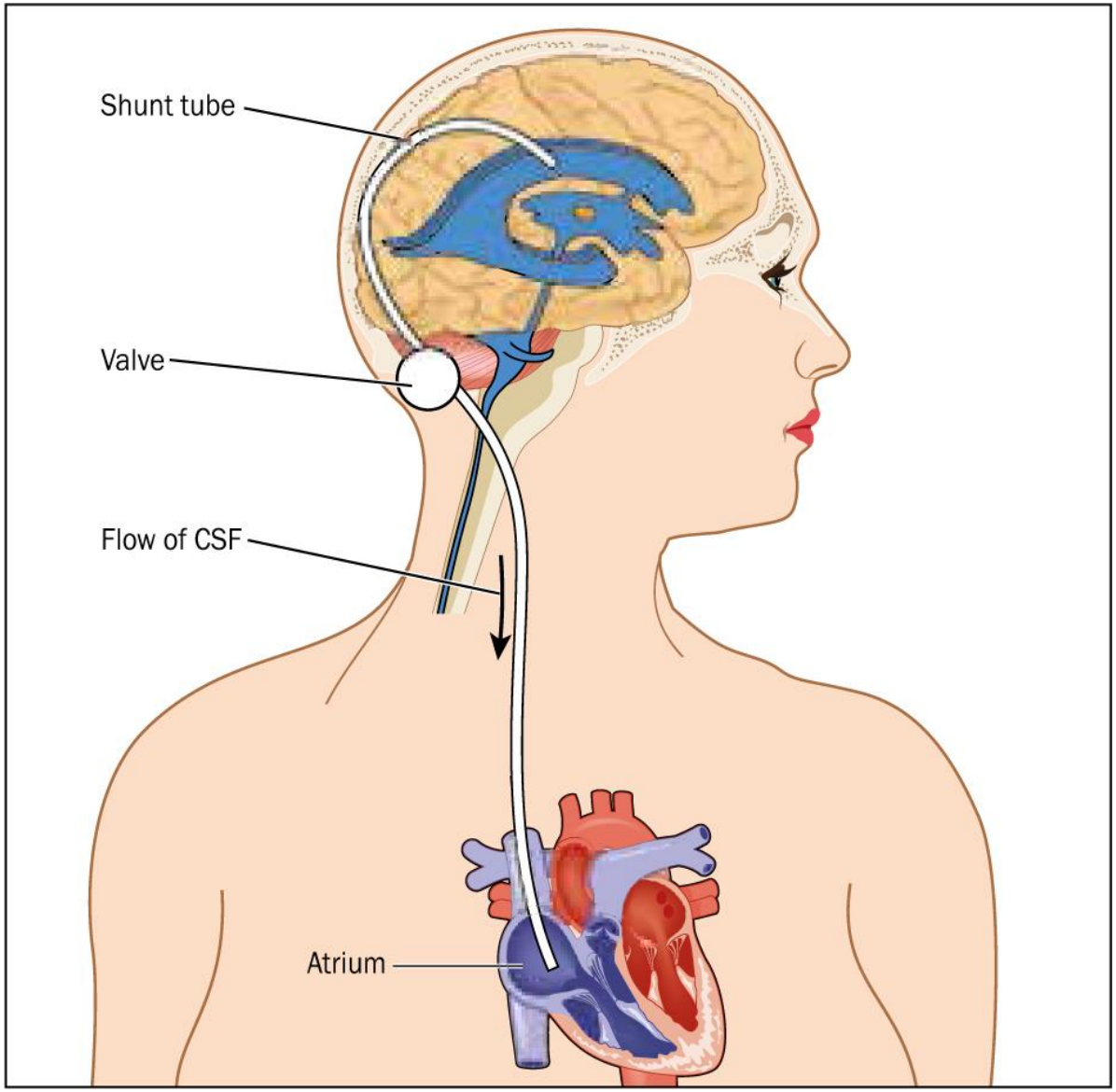

https://www.britishjournalofmidwifery.com/content/clinical-practice/cerebrospinal-fluid-shunts-in-the-maternity-context/

Neuro Restorative™
Rebuilding Lives. Restoring Hope.

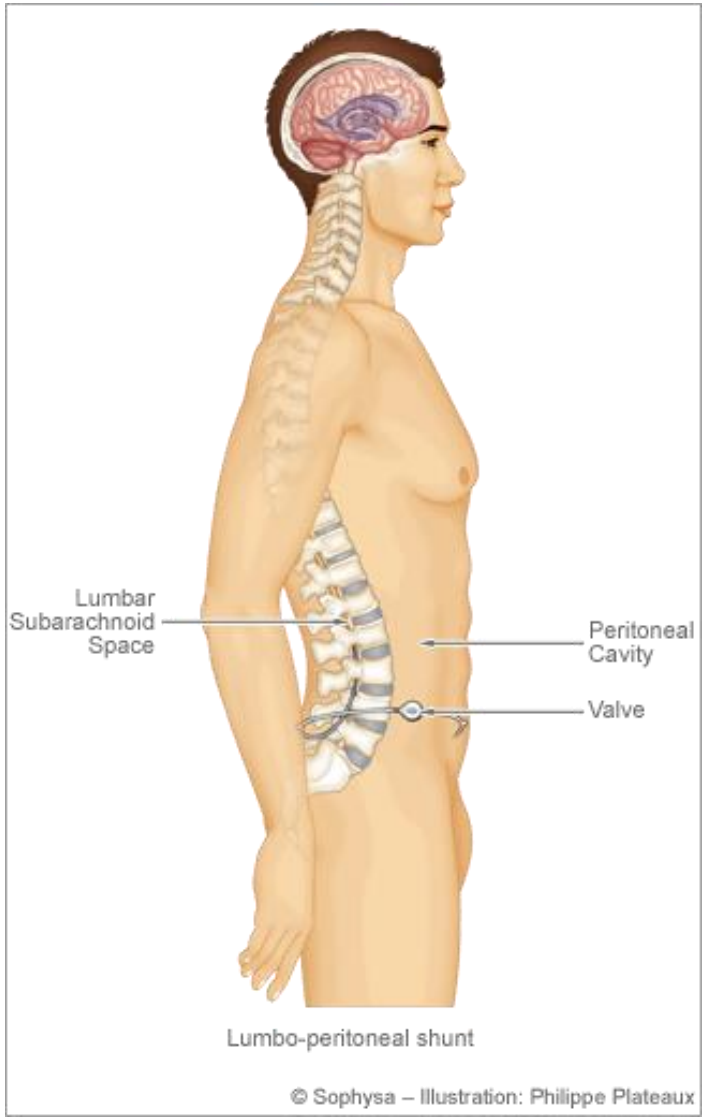

https://www.pacificneuroscienceinstitute.org/hydrocephalus/treatment/shunt-procedures/lumboperitoneal-shunt/

Medication

Limited evidence for medication use for hydrocephalus:

- Acetazolamide
- Furosemide

https://www.msmc.com/top-510-mistakes-people-make-with-prescription-medication/

So what happened to our patients?

Neuro Restorative™
Rebuilding Lives. Restoring Hope.

- She was admitted and underwent high volume LP, which had equivocal results.
- Shunting was deferred initially, but it was later decided to move forward with VP shunt placement.
- She continued follow up in TBI clinic where continued improvement in gait, cognition, and incontinence improved.

Take home points

- Clinical presentation tends to be gradual.
- You must maintain a high clinical suspicion.
- LPs/drainage can have equivocal results.
- Shunt is the only definitive treatment.

References

- Guyot LL, Michael DB. Post-traumatic hydrocephalus. Neurol Res. 2000 Jan;22(1):25-8. doi: 10.1080/01616412.2000.11741034. PMID: 10672577.
- Demerdash, A., Singh, R., Loukas, M. *et al.* A historical glimpse into treating childhood hydrocephalus. *Childs Nerv Syst* **32**, 405–407 (2016). https://doi.org/10.1007/s00381-015-2652-3
- Rufus P, Moorthy RK, Joseph M, Rajshekhar V. Post Traumatic Hydrocephalus: Incidence, Pathophysiology and Outcomes. Neurol India 2021;69, Suppl S2:420-8
- Tian HL, Xu T, Hu J, Cui YH, Chen H, Zhou LF. Risk factors related to hydrocephalus after traumatic subarachnoid hemorrhage. Surg Neurol. 2008 Mar;69(3):241-6; discussion 246. doi: 10.1016/j.surneu.2007.02.032. Epub 2007 Aug 17. PMID: 17707493.
- Sun S, Zhou H, Ding Z-Z, Shi H. Risk Factors Associated with the Outcome of Post-Traumatic Hydrocephalus. Scandinavian Journal of Surgery. 2019;108(3):265-270. doi:10.1177/1457496918812210
- Passos-Neto CEB, Lopes CCB, Teixeira MS, Studart Neto A, Spera RR. Normal pressure hydrocephalus: an update. Arq Neuropsiquiatr. 2022 May;80(5 Suppl 1):42-52. doi: 10.1590/0004-282X-ANP-2022-S118. PMID: 35976308; PMCID: PMC9491444.

Neuro Restorative™
Rebuilding Lives. Restoring Hope.

THANK YOU

Email: Clausyl.j.plummer@vumc.org

Twitter: @CJPHEALTH

Questions?